



Mitral Valve Disease

Zoltan G. Turi, MD



The mitral valve is the most complex of the heart's 4 valves and is the one most commonly associated with disease. There are 3 main conditions that affect the valve: Obstruction (stenosis), leakage (regurgitation), and bulging backward during valve closure (prolapse). Prolapse is the most common, occurring in up to 5% of the population, whereas stenosis is the least common, accounting for less than 1% of cardiac diagnoses in the United States, although it is more frequently seen in developing nations.

Structure and Function of the Mitral Valve

After blood receives oxygen in the lungs, it enters the left atrium. The mitral valve has 2 leaflets arranged to form a ring and a complex supporting structure consisting of muscles and tendons that support the leaflets like the strings on a parachute. The valve leaflets are normally thin and have an eyelid-like appearance (insets in Figure 1A and Figure 2A). The mitral valve acts as a gate between the left atrium and the left ventricle; the leaflets open and close as the heart beats and act as a 1-way valve. During diastole, when the left ventricle is relaxed, the valve opens and permits blood to flow from the atrium to the ventricle (Figure 1A). The valve then

closes during systole when the left ventricle ejects blood to the rest of the body, thus normally preventing blood from leaking back into the left atrium (Figure 2A).

Diagnosing Mitral Valve Disease

Experienced physicians can frequently make at least a preliminary diagnosis of mitral valve disease by listening to heart sounds with the stethoscope. Echocardiography (ultrasound) is particularly well suited to diagnosing mitral valve disorders. It can give useful guidance for determining what type of treatment will be optimal and can be used to periodically assess the effectiveness of any treatment. A special type of echo that involves swallowing a small tube with an echo probe on its end allows evaluation of the mitral valve from inside the esophagus. This test, called a transesophageal echocardiogram (TEE), is a particularly effective technique for ascertaining details of the mitral valve's structure and function.

Mitral Stenosis

Obstruction of or narrowing of the mitral valve is known as mitral stenosis, which can be caused by rheumatic fever after an untreated streptococcal infection such as a strep throat. The

availability of antibiotics has led to such a dramatic decrease in the incidence of rheumatic fever that mitral stenosis is now an uncommon condition in most industrialized nations. In developing countries, however, the disease remains relatively common, particularly in young women, and may first appear as a problem during pregnancy, a setting in which blood volume increases dramatically because of the presence of the fetus. The obstructed mitral valve acts like a dam, preventing the blood from emptying from the lungs and causing breathlessness (Figure 1B). Because the left atrium stretches in response to the backup of blood, the electrical pathways that keep the heart rhythm stable can become disturbed, and a rapid irregular heartbeat may result, causing palpitations. Other symptoms may include fatigue, chest pain, dizziness, and occasionally coughing up blood.

The only effective medical treatment is designed to slow the heart rate, allowing a longer period for blood to move from the left atrium into the left ventricle. Although this helps some patients feel better, it does not slow the progression of the disease. Anticoagulation (thinning the blood) can be an important method of preventing strokes, particularly in patients with irregular heart rhythms.

From the University of Medicine and Dentistry of New Jersey/Robert Wood Johnson Medical School, Camden, NJ.
Correspondence to Zoltan G. Turi, MD, Structural Heart Disease Program, Cooper University Hospital, One Cooper Plaza D-385, Camden, NJ 08103.
E-mail Turi-Zoltan@cooperhealth.edu

(*Circulation*. 2004;109:e38-e41.)

© 2004 American Heart Association, Inc.

Circulation is available at <http://www.circulationaha.org>

DOI: 10.1161/01.CIR.0000115202.33689.2C

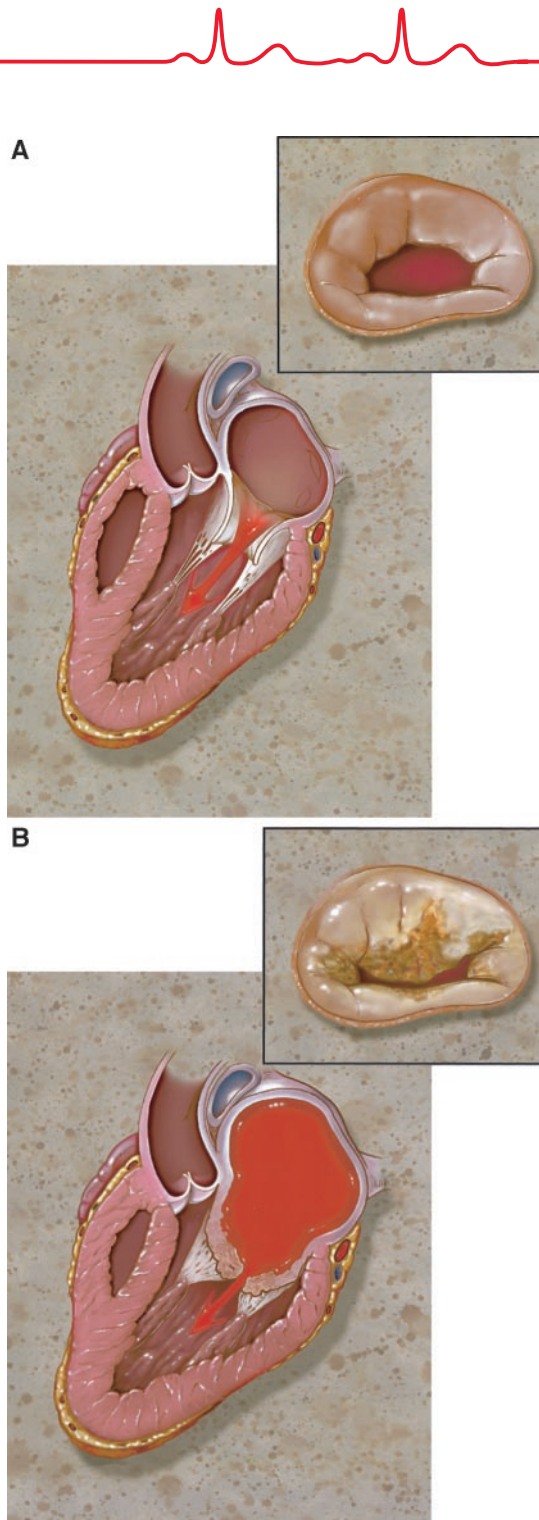


Figure 1. The heart in diastole (during relaxation of the left ventricle). A, In normal individuals, the heart valve opens to allow blood to flow into the left ventricle; notice the supporting structure of tendon and muscle. B, In patients with mitral valve stenosis, the valve has a characteristic domed appearance, restricted opening, and is thickened. The left atrium is typically enlarged.

There are 2 definitive treatments for mitral stenosis. For patients whose valves are not too calcified and do not leak severely, the blockage can fre-

quently be relieved without surgery by inflating a balloon to open the valve (the procedure is known as valvuloplasty). In the United States, valvulo-

plasty is available in specialized centers. For patients with severely diseased valves, especially older patients with calcium buildups or patients whose valves leak significantly, valve surgery is the best treatment. Most patients who are not candidates for ballooning have the valve replaced with an artificial tissue or plastic valve. In some cases, the diseased valve can be surgically repaired rather than replaced.

After valvuloplasty or mitral valve surgery, most patients will have significant improvement of symptoms. Anticoagulation is frequently continued because the risk for clots forming persists, especially if the heart rhythm remains abnormal. Patients with tissue heart valve replacements whose heart rhythms are normal may be able to avoid anticoagulation. Patients who have valvuloplasty usually have sustained improvement for a decade or more, but re-blockage of the valve can occur, and repeated ballooning or valve replacement may be necessary. Patients with artificial heart valves, particularly tissue heart valves, also can have recurrence of disease.

Mitral Regurgitation

When the mitral valve does not close completely during contraction of the left ventricle and blood leaks from the ventricle into the atrium, mitral regurgitation occurs (Figure 2B). It can be caused by mitral valve prolapse, by damage caused by rheumatic fever or valve infection, or by damage caused by a heart attack in the muscle attached to the heart valve. A relatively common cause of regurgitation is enlargement of the left ventricle, which results in stretching the ring of the mitral valve, causing the leaflets to close inadequately. Such enlargement may be caused by years of untreated high blood pressure or alcohol abuse; it can also be caused simply by chronic leakage of the mitral valve. Rarely, one or more of the string-like tendons attached to the heart valve can snap, causing massive and sudden leakage of

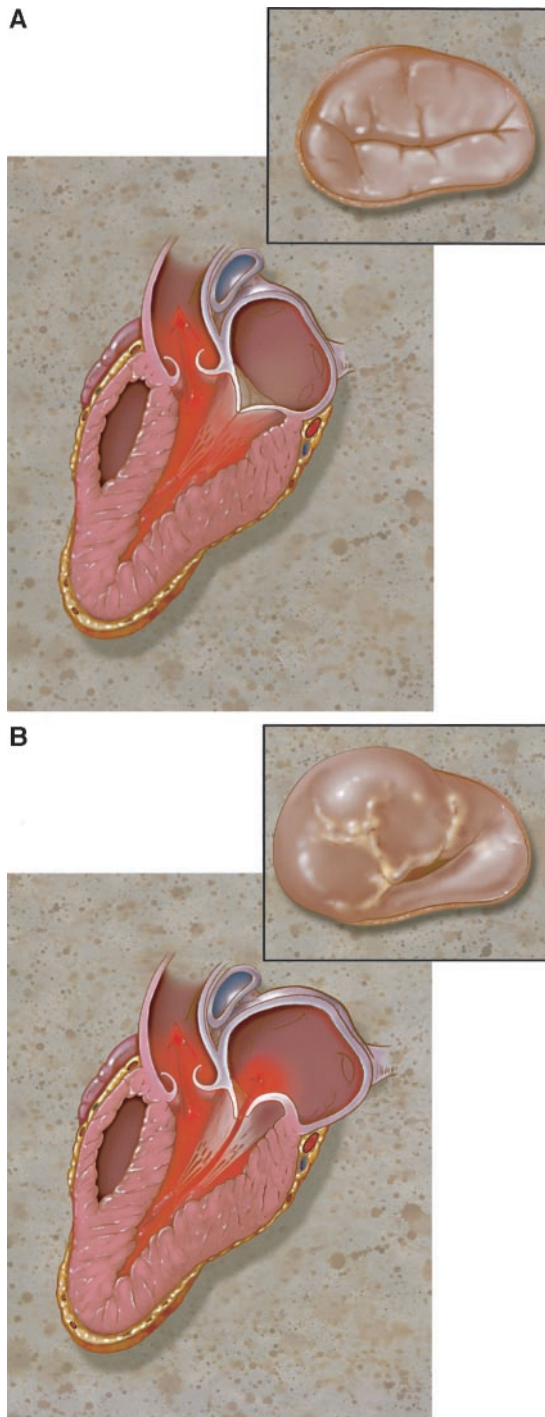


Figure 2. The heart in systole. During contraction of the left ventricle, the heart muscle is thicker. A, In normal individuals, the valve has closed, and no blood will leak backward into the left atrium. B, In the patient with both prolapse and mitral regurgitation, the valve does not close completely and part of a leaflet bulges back into the left atrium. There may be enlargement of the left ventricle, an effect of chronic severe regurgitation.

blood. Thus, depending on the cause, mitral regurgitation can develop suddenly or gradually.

When the leaking develops gradually, chronic mitral regurgitation may exist for years before symptoms de-

velop. The heart compensates by increasing the size of the left ventricle. As more blood is pumped backward into the left atrium and lungs, patients become breathless, fatigued, and can become progressively disabled. Medication is of limited benefit, although certain drugs that lower blood pressure or decrease the amount of fluid in the body (diuretics) may provide some help. When surgery is required, the timing of surgery is important, ideally being neither too early (and exposing the patient to the risk of operation before it is necessary) or too late (when the heart muscle is weakened and unable to withstand surgery). Whenever possible, the valve is repaired, although even in the most experienced hands some patients will require valve replacement. Long-term survival is excellent if surgery is performed before the heart becomes too dilated or weak, particularly if the valve can be repaired rather than replaced.

Acute (sudden) mitral regurgitation is an uncommon condition usually caused by infection of the heart valve or by sudden disruption of the valve structure, such as rupture of one of the supporting muscles early after a heart attack. Patients with this condition are acutely ill and usually require emergency replacement of the heart valve.

Mitral Valve Prolapse

Mitral valve prolapse (Figure 2B) is a common condition, occurring most frequently in women; some types are hereditary. There is some relationship between mitral valve prolapse and a variety of symptoms, including chest pain, fatigue, weakness, and perhaps even panic attacks. Mitral regurgitation is the most common heart problem associated with mitral valve prolapse; although usually mild, it can be progressive. In a very small percentage of patients, mitral valve prolapse has been associated with heart rhythm disturbances, infection of the heart valve, stroke, and very infrequently, sudden death (probably because of a rarely occurring rhythm abnormality). It is



important to note that the vast majority of mitral valve prolapse patients have a normal life expectancy and have no long-term medical problems associated with the condition.

Diagnosis of mitral valve prolapse is often made by physical examination. Echocardiography is used to confirm the diagnosis and assess the degree of mitral regurgitation. Patients without mitral regurgitation, heart rhythm disturbances, or certain associated illnesses and with otherwise normal heart are typically considered at low risk for long-term problems. Other patients, especially those with substantial regurgitation, are at risk for infection of the valve and may require preventive antibiotics before certain dental

and surgical procedures. Drugs that decrease the force with which the heart muscle contracts (beta blockers) and block the effect of the higher adrenalin levels seen in some mitral valve prolapse patients may alleviate symptoms. Avoiding caffeine, alcohol, and cigarettes may prevent the need for medication.

Conclusion

Disorders of the mitral valve are the most common of the valvular heart diseases. Mitral stenosis, although infrequent in the United States, remains a major medical problem worldwide. Medical therapy may provide symptomatic improvement. Minimally invasive approaches using balloons are

available for some patients, whereas heart surgery to repair or replace the valve will be required in others. Mitral regurgitation occurs more often and needs to be treated with surgery once sufficiently severe or when dictated by signs of decreasing heart function and increasing heart size. Mitral valve repair is preferable to replacement when possible. Mitral valve prolapse is not usually a harmful condition, although it can lead to significant mitral regurgitation or other problems in a small minority. Antibiotic prophylaxis should be considered before certain dental and surgical procedures in patients with any of these conditions, although not every patient with prolapse requires treatment.